

# *Borrelia burgdorferi* Persists in the Gastrointestinal Tract of Children and Adolescents with Lyme Disease

Martin D. Fried, MD\*<sup>†</sup>; Dorothy Pietrucha, MD<sup>†</sup>; Gaye Madigan, RN<sup>†</sup>; and Aswine Bal, MD<sup>§</sup>

## ABSTRACT

This study documents the persistence of *B burgdorferi* DNA in the gastrointestinal tract of pediatric patients who have already been treated with antibiotics for Lyme disease. Ten consecutive patients between the ages of 9 and 13 years presented with an erythema migrans (EM) rash, a positive western blot for Lyme disease, chronic abdominal pain, heartburn, or bright red blood in the stool. Endoscopy assessed the gastrointestinal (GI) mucosa for inflammation and biopsies were examined for *B burgdorferi* using a Dieterle stain and with polymerase chain reaction (PCR) to the outer surface protein A (Osp A) of *B burgdorferi*. As con-

trols, 10 consecutive patients with chronic abdominal pain were also tested by GI biopsies and PCR. *B burgdorferi* persisted in the GI tract in all 10 patients with Lyme disease as shown by Dieterle stain of biopsies and with PCR. None of the control subjects' biopsies were PCR positive for *B burgdorferi*. Chronic gastritis, chronic duodenitis, and chronic colitis were found in Lyme disease patients and associated with the detection of *B burgdorferi* DNA in the GI tract despite prior antibiotic treatments. We have concluded that the DNA of *B burgdorferi* persisted in patients with Lyme disease even after antibiotic treatment.

Key words: Lyme disease, abdominal pain, heartburn, blood in the stool, *B burgdorferi*, gastritis, duodenitis, colitis, polymerase chain reaction

## INTRODUCTION

Two previous studies have described the presence of *B burgdorferi* in the stomach, intestines, and colon of children.<sup>1,2</sup> To address the possibility of the persistence of *B burgdorferi* in the gastrointestinal (GI) tract, a prospective study was made of 10 consecutive patients who had a physician-documented erythema migrans (EM) rash followed by symptoms of Lyme disease that persisted for a year before diagnosis and antibiotic treatment was instituted. They had chronic GI symptoms that persisted during this same period and after completing antibiotic therapy. The purpose of this study is to address the possibility of persistence of *B burgdorferi* DNA after antibiotic treatment in patients with Lyme disease.

From the \*Departments of Pediatric Gastroenterology, <sup>†</sup>Pediatric Neurology, <sup>‡</sup>Academic Affairs, and <sup>§</sup>Pediatric Infectious Disease, Jersey Shore Medical Center, Neptune, New Jersey.

Address correspondence to Martin D. Fried, MD, 1945 Route 33, Neptune, NJ 07753.

## MATERIAL AND METHODS

All of the patients included in our study had an EM rash with no prior history of GI complaints. They were referred to the Pediatric Gastroenterology and Nutrition Service of Jersey Shore Medical Center for evaluation of chronic abdominal pain, heartburn, or bright red blood in the stool that persisted for at least one year after the onset of the EM rash. In all cases, antibiotic therapy for the treatment of Lyme disease was instituted one year after the EM rash and initial symptoms of Lyme disease. Ten consecutive patients satisfying the above clinical criteria<sup>3</sup> were evaluated prospectively from January 1993 through July 2000. There were 5 boys and 5 girls evaluated (mean age 14±3.6 years, range 9-12). Each case included a history, physical examination, complete blood cell count, liver function tests, esophagoduodenoscopy (EGD), and/or colonoscopy. One year after the EM rash, a Lyme IgG western blot confirmed a *B burgdorferi* infection by using the commercially available Marblot strip test system (MarDx Diagnostics, Carlsbad, CA). A positive western blot contained the presence of 5 or more of the following *Borrelia* bands: 18, 23, 28, 31, 34, 39, 41, 45, 58, 66, 93kDa. The interpretation of the *B burgdorferi*

Reprinted with permission; SLACK Incorporated, © 2002. All rights reserved.

western blot satisfied the surveillance case definition of *B burgdorferi* infection of the Centers for Disease Control and Prevention. Ultrasonography of the abdomen was performed when the history suggested a diagnosis of biliary tract disease, gallstones, or pancreatitis. Stool samples were examined for occult blood, *Salmonella*, *Shigella*, *Yersinia*, *Campylobacter*, ova and parasites, and *Clostridium difficile* toxins A and B. GI biopsies assessed the mucosa by microscopy for *Helicobacter pylori* (on EGD) and for the presence of *B burgdorferi* by Dieterle stain.

Biopsy specimens were taken from areas of the GI tract that looked inflamed during EGD or colonoscopy. The biopsies were repeated on the dates shown in the **Table** because of the persistence of GI complaints despite the antibiotic treatment of Lyme disease. The biopsies were randomly assigned to five histopathologists who were blinded to the diagnosis of the specimens they received. Biopses were reported as acutely inflamed when polymorphonuclear cells were present in the mucosa and chronically inflamed if 6 or more plasma cells and lymphocytes were present in the gastric mucosa without polymorphonuclear cells. Chronic duodenitis or chronic colitis was diagnosed when greater than 6 intraepithelial lymphocytes per 100 surface absorptive cells were present in tissue biopsies in conjunction with a distortion in glandular architecture.

A polymerase chain reaction (PCR) to detect the DNA of *B burgdorferi* outer surface protein A (Osp A) was performed on all biopsies by Medical Diagnostic Laboratories, New Jersey.

#### DNA Extraction

As a target for DNA amplification, the gene coding for the Osp A of *B burgdorferi* was analyzed. The tissue was dissolved in 470  $\mu$ L of tris-edetic acid (EDTA) buffer (10 mM tris-hydrochloride [pH, 8.0] and 1 mM EDTA), 25  $\mu$ L of 10% sodium dodecyl sulfate, and 12  $\mu$ L of freshly prepared deoxyonuclease-free proteinase K (10 mg/mL). The mixture was incubated at 55°C for 2 hours; DNA was extracted with phenolchloroform extraction and ethanol precipitation. The purified DNA was dissolved in pyrogen-free, double distilled water and quantified using a Genesys-5 spectrophotometer (Spectronic Instruments, Rochester, NY). The purified quantitated DNA was used as a template for *B burgdorferi* PCR analysis.

#### Primers

The PCR primers for the identification of *B burgdorferi*, as well as the sensitivity and specificity of the *B burgdorferi* primers are well described. The primers were synthesized by Research Genetics (Huntsville, AL) and purified by high-performance liquid chromatography.

#### Polymerase Chain Reaction

The PCR mixtures (50  $\mu$ L) contained extracted DNA (5  $\mu$ L, 2  $\mu$ g/ $\mu$ L), P24E, and P12B primers (50 nM), 10 mM trishydrochloride (pH 8.3), 50 mM potassium chloride, 3 mM magnesium chloride, 0.001% (wt/vol) gelatin, the nucleotides dATP, dCTP, dGTP, and dTTP (each at concentrations of 200 mmol/L), and 2.5 U of Taq DNA polymerase (Perkin-Elmer, Foster City, CA). The PCR was carried out in 0.2 mL tubes. The thermocycler was a Perkin-Elmer Gene AMP PCR system 2400. The PCR program ran for 3 minutes at 94°C, followed by 40-one minute cycles at 94°C, 1 minute at 56°C, and 1.5 minutes at 72°C. The program finished with an additional 10-minute extension step at 72°C. A 30  $\mu$ L sample of the final reaction product was run on 1% agarose gel containing 0.5  $\mu$ g of ethidium bromide per mL, and the gel was photographed under ultra violet (UV) light.

#### Histone PCR

Alliquots (5  $\mu$ L) of the newly extracted DNA were mixed in a 50  $\mu$ L PCR reaction mixture containing 10X PCR buffer (Perkin-Elmer), 3 mM magnesium chloride, 200 mM dNTP, 2.5  $\mu$ L of Taq DNA polymerase (5 U/ $\mu$ L), and 1  $\mu$ L (8 pmol) of 5' and 3' histone amplifier primer set. The histone primers are complementary to the DNA of a constitutively expressed human histone gene H3.3 as described. The amplification process was subjected to 30 cycles of PCR (each cycle at 94°C for 45 seconds, 60°C for 45 seconds, and 72°C for 90 seconds) in a 2400 Perkin-Elmer DNA thermocycler. The histone primers served as internal controls for the sample's DNA integrity, presence of inhibitors, and intersample equivalency of total amount of DNA analyzed.

#### Precautions Against Contamination

The extraction of DNA and PCR were performed under sterile conditions and in separate rooms. All positive samples were confirmed by re-extraction from the original sample, followed by amplification in triplicate. DNA-positive status was defined as samples that were positive initially and in at least one of the replicates after re-extraction. Pyrogen-free water was used in the isolation of DNA from the biopsy specimens. The Eppendorif microcentrifuge tubes and the PCR tubes were sterilized in an autoclave and UV irradiated. New Finn pipettes were used solely with the filter tips for PCR. Disposable plastic trays were used to prepare PCRs in a UV irradiated PCR biohood. GI biopsy samples from 10 patients with chronic abdominal pain who had no history of tick-borne disease or antibiotic use in the year prior to endoscopy were used in the PCR assays as negative controls. The laboratory performing the PCR analysis was blinded to the diagnosis of all specimens they received.

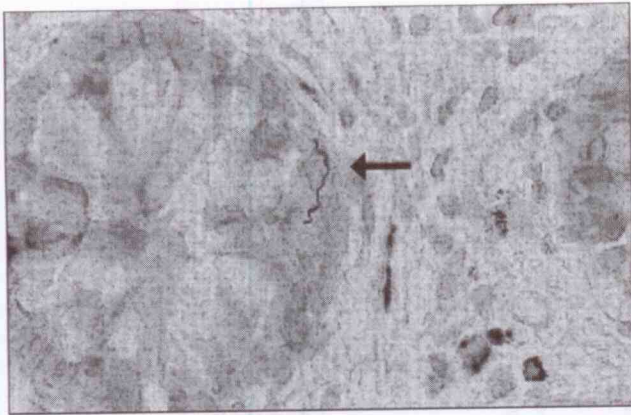

Figure 1. Colon biopsy specimen from a patient with Lyme disease. Abdominal pain and blood in the stool were symptoms. Arrow shows typical helical-shaped spirochete characteristic of *Borrelia burgdorferi* (Dieterle stain-magnification x522).




Figure 2. A spirochete (arrow) consistent with the microscopic appearance of *Borrelia burgdorferi* is seen in the basal layer of the columnar epithelium from a duodenal biopsy specimen of a patient with Lyme disease and chronic abdominal pain (magnification x790).

## RESULTS

Lyme disease patients presented with chronic abdominal pain and heartburn (n=4, 40%), or chronic abdominal pain and bright red blood in the stool (n=6, 60%). All 10 patients had evidence of inflammation at a GI biopsy site with the microscopic detection of *B burgdorferi* by Dieterle stain that was also confirmed by the detection of *B burgdorferi* DNA by PCR despite 2 prior months of antibiotic therapy (**Figures 1 and 2**). Two of the control patients (#4, #7) had antral gastritis and *H pylori* on biopsy but no evidence of *B burgdorferi* on microscopy or PCR in biopsy specimens from the GI tract (**Table**).

In patients 1 and 10, *B burgdorferi* DNA was detected in the colon on 2 separate colonoscopies performed at least 4 years apart after having received 2 months of intravenous antibiotics for the treatment of Lyme disease. The biopsies of all the Lyme disease patients revealed no evidence of granulomas or terminal ileitis. The IgG western blot was positive in all the patients and negative in all of the control patients. *Salmonella*, *Shigella*, *Yersinia*, *Campylobacter*, and *Clostridium difficile* toxins A and B were not detected in any of the stool samples from patients or controls.

Ultrasonography of the abdomen did not reveal any gallstones, biliary tract disease, or evidence of pancreatitis. The lab performing the PCR had a false positive rate of 1 in 500 by analyzing 25,000 specimens from January 1998 through January 2002.

## DISCUSSION

The persistence of Lyme disease as seen by light microscopy and confirmed by tissue PCR in patients with chronic GI symptoms has not been described before.

Oksi<sup>3</sup> described the use of PCR in clinical relapse of disseminated Lyme borreliosis to guide the use of additional antibiotic therapy. According to Oksi, the treatment of Lyme borreliosis with appropriate antibiotics for even more than 3 months may not always eradicate the spirochete. The biopsy and PCR results described here suggest the persistence of *B burgdorferi* in the stomach, duodenum, and colon at the sites of inflammation despite antibiotic therapy.

Several other authors have suggested that *B burgdorferi* may persist in humans and animals for months or years, despite strong humoral or immune responses.<sup>4-7</sup> One possible explanation for this persistence is the failure of the host to produce borreliacidal Osp A antibodies. Another possible explanation is the invasion of poorly vascularized connective tissues by spirochetes or even an intracellular location of spirochetes.<sup>8-11</sup>

Other etiologic infections that are also transmitted by a tick bite should be considered in the differential diagnosis of heartburn, abdominal pain, and blood in the stool in Lyme disease patients with persistent symptoms. Coinfection with either Babesia, Ehrlichia, and Bartonella have recently been reported.<sup>12-14</sup> In areas where both babesiosis and Lyme disease have been reported, the possibility of concomitant babesial infection should be considered. In one such study<sup>14</sup> of 240 patients diagnosed with Lyme disease, 26 (11%) were coinfecting with babesiosis. These coinfecting patients experienced fatigue, headache, sweats, chills, anorexia, nausea, and splenomegaly more frequently ( $P < 0.05$ ) than those with Lyme disease alone. This pathogen may survive Lyme antimicrobial therapy and be one of the agents responsible for causing persistent symptoms in Lyme disease patients.

Table. The biopsy results of patients with chronic persistent abdominal pain and Lyme disease versus controls.

Patient No	Sex	Age	Diagnosis Date	Chief Complaint	Antibiotics (months)*	Date of Biopsy	Gastric Biopsy	Gastric PCR	Duodenal Biopsy	Duodenal PCR	Colon Biopsy	Colon PCR
<b>Controls</b>												
1	F	17	April 1999	Abdominal pain	0	April 1999	(-)**	(-)	(-)	(-)	(-)	(-)
2	F	14	April 1999	Abdominal pain	0	April 1999	(-)	(-)	(-)	(-)	(-)	(-)
3	F	11	March 1993	Abdominal pain	0	March 1993	(-)	(-)	(-)	(-)	(-)	(-)
4	M	17	January 1996	Abdominal pain	0	January 1996	<i>H pylori</i>	(-)	(-)	(-)	(-)	(-)
5	F	15	February 1998	Abdominal pain	0	February 1998	(-)	(-)	(-)	(-)	(-)	(-)
6	F	8	February 1995	Abdominal pain	0	February 1995	(-)	(-)	(-)	(-)	(-)	(-)
7	F	15	April 1999	Abdominal pain	0	April 1999	<i>H pylori</i>	(-)	(-)	(-)	(-)	(-)
8	F	17	April 1999	Abdominal pain	0	April 1999	(-)	(-)	(-)	(-)	(-)	(-)
9	F	16	January 1993	Abdominal pain	0	January 1993	(-)	(-)	(-)	(-)	(-)	(-)
10	M	13	March 1999	Abdominal pain	0	March 1999	(-)	(-)	(-)	(-)	(-)	(-)
<b>Lyme Disease Patients</b>												
1	M	9	January 1993	Abdominal pain, blood in stool	4	March 1993	Gastritis	DNA†	Duodenitis	(-)	Bb,‡ colitis	DNA
			December 1998	Abdominal pain, blood in stool	4	February 1999	(-)	(-)	(-)	(-)	Colitis	DNA
2	M	13	January 1999	Abdominal pain, blood in stool	2	March 1999	(-)	(-)	(-)	(-)	Bb, colitis	DNA
			February 2000	Abdominal pain, blood in stool	2	April 2000	(-)	(-)	(-)	(-)	Colitis	DNA
3	F	12	December 1994	Abdominal pain, heartburn	4	February 1995	Gastritis	(-)	Bb, duodenitis	DNA		
			January 1999	Abdominal pain, heartburn	5	March 1999	Gastritis	(-)	Duodenitis	DNA		
4	F	7	March 1997	Abdominal pain, heartburn	2	May 1997	Bb, gastritis	DNA	(-)	(-)		
			March 1999	Abdominal pain, heartburn	2	May 1999	Gastritis	DNA	(-)	(-)		
5	F	11	December 1992	Abdominal pain, heartburn	2	February 1993	Gastritis	(-)	Bb, duodenitis	DNA		
			April 1993	Abdominal pain, heartburn	2	June 1993	(-)	(-)	Duodenitis	DNA		
6	M	9	March 1993	Abdominal pain, blood in stool	2	May 1993	(-)	(-)	(-)	(-)	Bb, colitis	DNA
			May 1994	Abdominal pain, blood in stool	2	July 1994	(-)	(-)	(-)	(-)	Colitis	DNA
7	F	10	February 1995	Abdominal pain, heartburn	5	April 1995	Bb, gastritis	DNA	(-)	(-)		
			January 1999	Abdominal pain, heartburn	4	March 1999	Gastritis	DNA	(-)	(-)		
8	M	12	January 1999	Abdominal pain, blood in stool	2	March 1999	(-)	(-)			Bb, colitis	DNA
			January 2000	Abdominal pain, blood in stool	2	March 2000	(-)	(-)	Bb, duodenitis	DNA	Colitis	DNA
9	M	11	June 1993	Abdominal pain, blood in stool	4	August 1993	Gastritis	DNA	Duodenitis	DNA	Bb, colitis	DNA
			June 1994	Abdominal pain, blood in stool	4	August 1994	Gastritis	DNA	Duodenitis	DNA	Colitis	DNA
10	F	10	April 1994	Abdominal pain, blood in stool	2	June 1994	Bb, gastritis	DNA	Duodenitis	DNA	Bb, colitis	DNA
			December 1998	Abdominal pain, blood in stool	4	February 1999	Gastritis	DNA	Duodenitis	DNA	Colitis	DNA

\*Number of months of antibiotic treatment for Lyme disease prior to endoscopy in the last year.

\*\* (-) denotes no histological pathology detected on biopsy and no detection of *B burgdorferi* DNA by polymerase chain reaction (PCR).†DNA denotes the detection of *B burgdorferi* DNA (the outer surface protein A) by PCR of biopsy specimens. DNA denotes the detection of *B burgdorferi* DNA.‡Denotes the microscopic appearance of *B burgdorferi* on biopsy specimens with the use of a Dieterle stain.

Unfilled spaces denotes areas of the gastrointestinal tract that were not biopsied.

## CONCLUSION

Inflammation found in the stomach, duodenum, and colon of patients with Lyme disease who had persistent heartburn, abdominal pain, or blood in the stool may be attributed to multiple etiologies, one of which is the presence and or persistence of Lyme DNA. Babesia, Ehrlichia, and Bartonella as etiologies of persistent GI symptoms unresponsive to Lyme antimicrobial therapy deserves further investigation.

## ACKNOWLEDGMENT

Special thanks to the Lyme Disease Association, Inc. for providing funding for this project. We also wish to thank all of the endoscopy and pediatric nurses at Jersey Shore Medical Center for caring for these patients.

## REFERENCES

1. Fried MD, Duray P, Pietrucha D. Gastrointestinal pathology in children with Lyme disease. *Journal of Spirochetal and Tick-Borne Diseases*. 1996;3:101-104.
2. Fried MD, Abel M, Pietrucha D, Yen-Hong K, Ball A. The spectrum of gastrointestinal manifestations in children and adolescents with Lyme disease. *Journal of Spirochetal and Tick-Borne Diseases*. 1999;6:89-93.
3. Oksi J, Marjamaski M, et al. *Borrelia burgdorferi* detected by culture and PCR in clinical relapse of disseminated Lyme borreliosis. *Ann Med*. 1999;31:225-232.
4. Appel M, Allen R, et al. Experimental Lyme disease in dogs produces arthritis and persistent infection. *J Infect Dis*. 1993;167:651-664.
5. Barthold S. Animal models for Lyme disease. *Lab Invest*. 1995;72:127-130.
6. Preac-Mursic V, Patsouris B, et al. Persistence of *B burgdorferi* and histopathological alterations in experimentally infected animals. A comparison with histological findings in human disease. *Infection*. 1990;18:332-341.
7. Sigal LH. Persisting symptoms of Lyme disease: possible explanations and implications for treatment. *J Rheumatol*. 1994;21:593-595.
8. Georgilis K, Peacocke M, Klempner MS. Fibroblasts protect the Lyme disease spirochete, *B burgdorferi*, from ceftriaxone in vitro. *J Infect Dis*. 1992;166:440-444.
9. Haupl T, et al. Persistence of *B burgdorferi* in ligamentous tissue from a patient with chronic Lyme borreliosis. *Arthritis Rheum*. 1993;36:1621-1626.
10. Klempner MS, Noring R, Rogers RA. Invasion of human skin fibroblasts by the Lyme disease spirochete *B burgdorferi*. *J Infect Dis*. 1993;167:1074-1081.
11. Ma Y, Sturrock A, Weis JJ. Intracellular localization of *B burgdorferi* within human epithelial cells. *Infect Immun*. 1991;59:671-678.
12. Eskow E, Rao RV, Mordechai E. Concurrent infection of the central nervous system by *B burgdorferi* and *Bartonella henselae*. *Arch Neurol*. 2001;58:1357-1363.
13. Mitchell PD, Reed KD, Hofkes JM. Immunoserologic evidence of coinfection with *B burgdorferi*, *Babesia microti* and human granulocytic Ehrlichia species in residents of Wisconsin and Minnesota. *J Clin Microbiol*. 1996;34:724-727.
14. Krause PJ, Telford SR III, Spielman A, et al. Concurrent Lyme disease and babesiosis. Evidence for increased severity and duration of illness. *JAMA*. 1996;276:1657-1660.